

UDC 616–08–035/616–006.524

Dmytro Shevchuk^{1,2,3}, Vitalii Zaremba¹, Andrii Vasianovych⁴

Endoscopic resection of bladder urothelial neoplasm in a child: a case report

¹Department of Surgery No. 2, Communal Institution Zhytomyr Oblast Children's Clinical Hospital of Zhytomyr Oblast State Administration, Ukraine

²Zhytomyr Ivan Franko State University of the MES of Ukraine

³Shupyk National Healthcare University of Ukraine, Kyiv

⁴Zhytomyr Oblast Morbid Anatomy Department of Zhytomyr Oblast State Administration, Ukraine

Paediatric Surgery(Ukraine).2022.2(75):89-95; doi 10.15574/PS.2022.75.89

For citation: Dmytro Shevchuk, Vitalii Zaremba, Andrii Vasianovych. (2022). Endoscopic resection of bladder urothelial neoplasm in a child: a case report. Paediatric Surgery(Ukraine). 2 (75): 89-95; doi 10.15574/PS.2022.75.89.

Bladder tumour, especially urothelial neoplasm, is a very rare condition in paediatric age. That is why true and accurate information on biological grade of malignancy and, correspondingly, the surgical management is absent. However, the majority of physicians take the view that this type of tumour has a low grade of malignization and recurrence, even after the endoscopic excision of neoplasm in paediatric patients.

Purpose – to describe a clinical case of surgical management of the bladder urothelial neoplasm in a child by means of minimally invasive equipment.

Clinical case. Endoscopic methods of surgical treatment are widely used in paediatric patients with the urinary tract conditions in our clinic. The transcutaneous surgical treatment of bladder conditions has been employed in paediatric patients since 2010. For example, it was used for the removal of ureterolith impacted in the bladder neck and foreign bodies of the bladder, as well as the bladder urothelial neoplasm excision.

We also tried to use it for visualisation of the posterior urethra rupture length through a cystoscope, which was put into the epicycstostomic hole of the posterior urethra together with the simultaneous urethroscopy (for the purpose of the directed illumination during the urethroscopy). However, due to the long length of the posttraumatic urethrostenosis, it was impossible to achieve the illumination and catheterisation of the urethra during the urethroscopy in the site of damage.

The clinical case of the minimally invasive resection of the bladder urothelial neoplasm in a child is presented in the article.

Minimally invasive techniques give the opportunity to perform even the radical operations with the perfect cosmetic result and minimal injury that is very important in the paediatric patients.

Keywords: bladder neoplasm, transcutaneous cystoscopy, neuromuscular bladder dysfunction, children.

Ендоскопічне видалення уротеліальної пухлини сечового міхура в дитини: випадок із практики

Д. В. Шевчук^{1,2,3}, В. Р. Заремба¹, А. В. Васянович⁴

¹КУ «Житомирська обласна дитяча клінічна лікарня Житомирської обласної ради», Україна

²Житомирський державний університет імені І. Франка МОН України

³Національний університет охорони здоров'я України імені П. Л. Шупика, м. Київ

⁴Житомирське обласне патологоанатомічне бюро Житомирської обласної ради, Україна

Новоутворення сечового міхура, зокрема уротеліальні пухлини, – дуже рідкісне захворювання в дитячому віці. Саме тому немає достовірної інформації стосовно ступеня малігнізації та відповідно обсягу хірургічного лікування. Однак більшість авторів схиляються до думки стосовно низького ступеня малігнізації та рецидивування, навіть після ендоскопічних методів видалення таких пухлин у дитячому віці.

Мета – описати клінічний випадок хірургічного лікування уротеліальної пухлини сечового міхура в дитини із застосуванням мініінвазивного обладнання.

Клінічний випадок

Клінічний випадок. В умовах хірургічного відділення нашої клініки широко впроваджені ендоскопічні методи хірургічного лікування патології сечовивідних шляхів у дітей. З 2010 р. впроваджено метод черезшкірного хірургічного лікування патології сечового міхура в дитячому віці. Так, виконано хірургічне втручання для видалення вклиненого в шийку конкременту, видалення сторонніх тіл сечового міхура та видалення уротеліальної пухлини сечового міхура.

Також зроблено спробу візуалізації протяжності розриву задньої уретри шляхом введення цистоскопа через епіцистостомічний отвір у ділянку задньої уретри та одночасного проведення уретроскопії (намагання побачити джерело світла при уретроскопії). Однак велика протяжність післятравматичної стриктури не дала змоги візуалізувати світло при уретроскопії та провести катетеризацію уретри в місці пошкодження.

У роботі наведено клінічний випадок із практики – мініінвазивне видалення уротеліальної пухлини сечового міхура в дитини.

Мініінвазивні методи дають змогу виконувати навіть радикальні оперативні втручання з відмінним косметичним результатом, мінімальним травматизмом, що має неабияке значення в дитячому віці.

Ключові слова: новоутворення сечового міхура, черезшкірна цистоскопія, нервово-м'язова дисфункція сечового міхура, діти.

Introduction

The diagnosis of bladder tumour is uncomplicated. Furthermore, the CT-virtual cystoscopy (computed tomography virtual cystoscopy) as a non-invasive diagnostic procedure is widely used for diagnosis of bladder neoplasms in the surgical practice now [4].

Usama N. Rifat et al. [12] analysed the PubMed and Hinari databases and found 57 publications described 127 clinical cases of the bladder urothelial neoplasms in children. Besides, the authors described two new cases of their own practice.

Dr. Alexis Litchinko et al. [8] from Switzerland also described a case of the cystotomic surgical treatment of transitional cell carcinoma in a 12-year-old boy with painless haematuria, and admitted that there was neither clear algorithm of surgical management of such a condition, nor convincing evidence concerning its malignization. The similar case was published by the Chinese researchers [6].

Berrettini A. et al. [2] analysed 18 paediatric patient treatment with the bladder urothelial neoplasms, who underwent the transurethral resection (TUR). They admitted that those tumours in paediatric practice had the low grade of recurrence (up to 7 per cent) and, as a rule, the surgical treatment was sufficient. Other researchers made the same conclusions [1,3,5,9–11,16].

Thus, to date the surgical minimally invasive treatment of bladder pathology is used to a great extent. Early we have reported about our experience of transcutaneous cystoscopy employment for the removal of foreign bodies of the bladder, etc [13,15].

Purpose – to report about the clinical case of the bladder urothelial neoplasm management in a child by means of surgical minimally invasive technique.

The endoscopic methods of surgical treatment are widely used in children with the urinary tract conditions in our clinic. The transcutaneous surgical treatment of bladder conditions has been employed in paediatric patients since 2010. For example, it was used for the removal of ureterolith impacted in the bladder neck and

foreign bodies of the bladder, as well as the bladder urothelial neoplasm excision.

We also tried to use it for visualisation of the posterior urethra rupture length through the cystoscope, which was put into the epicystostomic hole of the posterior urethra together with the simultaneous urethroscopy (for the purpose of the directed illumination during the urethroscopy). However, due to the long length of the posttraumatic urethrostenosis, it was impossible to achieve the illumination and catheterisation of the urethra during the urethroscopy in the site of damage.

Clinical case

We present a clinical case of the minimally invasive resection of the bladder urothelial neoplasm in a child and the follow-up management of our own experience.

An 11-year-old female child underwent inpatient treatment in our clinic from 05.10.2015 to 09.10.2015 with *the admission diagnosis*: bladder neoplasm. *The discharge diagnosis*: bladder neoplasm (the transitional cell papilloma). A bladder neoplasm was diagnosed during the outpatient routine examination in the community. The patient was referred to our clinic for further examination.

The complaints were absent at admission. The patient had no particular past medical history. The familial history was unremarkable. The patient's mother denied a close tuberculosis (TB) contact or sexually transmitted diseases (STDs). The physical examination and vital signs were within normal limits.

Additional clinical tests: complete blood count (CBC) with differential and clinical urinalysis (on the outpatient basis): within normal limits. Nechiporenko test: white blood cells (WBC) – $2.3 \times 10^6/L$, red blood cells (RBC) – $0.8 \times 10^6/L$. Biochemical blood test: creatinine – $46 \mu\text{mol}/L$, urea – $3.2 \text{ mmol}/l$, total protein – $66.6 \text{ g}/L$, serum albumin – $46 \text{ g}/L$. Bladder ultrasound conclusion: the bladder neoplasm revealed. The child was examined by paediatrician upon admission.

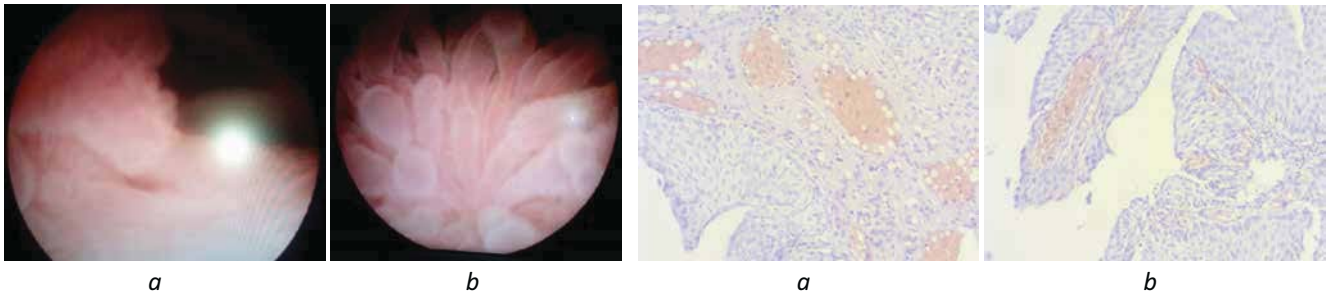


Fig. 1. Diagnostic cystoscopy, biopsy from 07.10.2015: a – the golf-hole-shaped ureteral orifices were identified; b – lesion along the lateral border of the right ureteral orifice with branchy epithelial excrescences
Fig. 2. Postoperative biopsic specimen (hematoxylin and eosin staining, $\times 200$) – transitional cell carcinoma

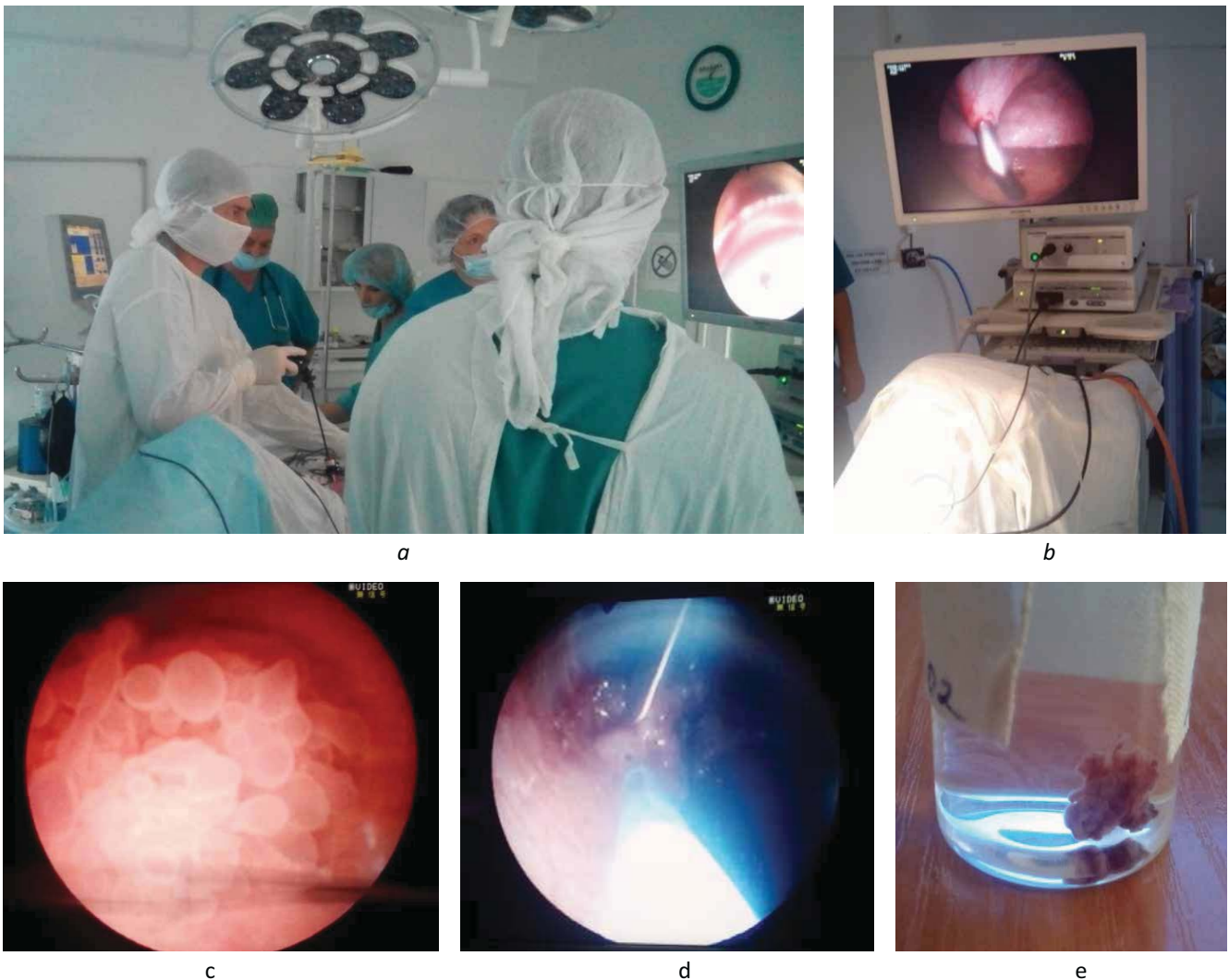


Fig. 3. Excision of neoplasm via transcutaneous cystoscopy on 30.10.2015. (a, b); lesion along the lateral border of the right ureteral orifice with branchy epithelial excrescences (c); the complete lesion excision by means of electrocoagulation (d); Postoperative gross specimen (e)

Treatment given: the diagnostic cystoscopy and neoplasm biopsy under the general anaesthesia was provided on 07.10.2015.

Operative steps: after preoperative showering the external genitalia with antibacterial soap, 11 Fr ureterorenoscope was inserted and the bladder was filling with 200 ml of 0.02% Furacilini. Then operative exploration

of the bladder was performed. The golf-hole-shaped ureteral orifices were identified (Fig. 1a), the mucosal surface had usual pink colour. There was a 2.0 cm lesion along the lateral border of the right ureteral orifice with branchy epithelial excrescences (Fig. 1b). A biopsy specimen was taken (Fig. 2). The bleeding from the biopsy site was minimal. The cystoscope together with

Клінічний випадок

solution of Furacilini was removed, and 18 Fr Foley catheter was installed.

The postoperative period was uneventful. The Foley catheter was removed on the second postoperative day. The patient discharged with improvement. Besides, the parents were advised to consult the child by oncologist in the tertiary referral centre with the aim of determining the subsequent treatment.

The planned readmission to our department was from 28.10.2015 to 11.11.2015 with *the admission diagnosis*: bladder neoplasm. *The discharge diagnosis*: bladder neoplasm (the transitional cell papilloma). The child was consulted by a specialist in the tertiary referral centre and surgical excision of tumour in the health facility at the place of residence was recommended.

The patient's past medical history was without changes compared with the previous admission. The patient's mother denied a close TB contact or STDs.

Additional clinical tests on admission: CBC: haemoglobin (HBG) – 128 g/L, RBC – $4.1 \times 10^{12}/L$, WBC – $5.0 \times 10^9/L$, erythrocyte sedimentation rate (ESR) – 5 mm/h; clinical urine analysis (UA): protein – 0.05 g/L, WBC – 20–25 per high power field (HPF), transitional epithelial cells – 1–2/HPF, 4–5 squamous epithelial cells/HPF, abnormal RBC – 8–10/HPF, non-lysed RBC – 10–15/HPF, 0–1 hyaline casts/HPF. Nechiporenko test: WBC – $2.3 \times 10^6/L$, RBC – $0.8 \times 10^6/L$. Biochemical blood test: creatinine – 59 $\mu\text{mol}/L$, urea – 3.5 mmol/L, total protein – 65.1 g/L, serum albumin – 46 g/L. Coagulogram: within normal limits. Ultrasonic scanning of bladder: the bladder neoplasm. Electrocardiogram (ECG): within normal limits. The child was examined by paediatrician upon admission. Physical examination and vital signs were within normal limits.

Treatment given: 30.10.2015 – surgery – transcutaneous cystoscopy, excision of neoplasm (Fig. 3a, b) under the general anaesthesia.

Operative steps: after preoperative showering the external genitalia with antibacterial soap, 11 Fr ureterorenoscope was inserted and the bladder was filling with Cytoclin™ up to 2 L during the intervention. Then operative exploration of the bladder was performed. The golf-hole-shaped ureteral orifices were identified, the mucosal surface has usual pink colour. There was a 2.0 cm lesion along the lateral border of the right ureteral orifice with branchy epithelial excrescences (Fig. 3c). In the pubic region under visual control two 5-mm ports were introduced. Then the insufflation of CO₂ was performed. Using a manipulator, the fixation and traction of neoplasm was made. Then the complete lesion excision along with surrounding normal tissue was conducted by means of electrocoagulation (Fig. 3d).

The removed tissues were submitted for the pathohistological study (Fig. 3e). The control of bleeding was performed during the surgical intervention. The bleeding was not detected. The cystoscope and with ports were removed. The surgical wounds were sutured and 14 Fr Foley catheter was installed.

The pathohistological study (No. 5538) was performed and the transitional cell papilloma was diagnosed (Fig. 4).

The postoperative period was uneventful. The bladder catheterization was performed during seven postoperative days. A symptomatic therapy was administrated. The patient was discharged recovered.

The patient was advised to continue follow-up by the paediatrician in the community, control urination, provide urinalysis weekly, continue taking the uroseptics in age sufficient doses during three weeks, and control bladder ultrasonography in 3 months with the consultation of paediatric urologist in our clinic.

The planned hospital admission to our clinic was from 08.06.2016 to 13.06.2016 with *the admission diagnosis*: bladder neoplasm (the transitional cell papilloma), postoperative period. Complaints at admission were not present. The patient's past medical history was without changes as compared with the previous admission.

Additional clinical tests: CBC: HBG – 132 g/L, RBC – $4.1 \times 10^{12}/L$, WBC – $8.2 \times 10^9/L$, ESR – 6 mm/h. UA: protein – negative, 3–4 WBC/HPF, sporadic transitional epithelial cells/HPF, sporadic squamous epithelial cells/HPF. Nechiporenko test: WBC – $0.5 \times 10^6/L$, RBC – $0.7 \times 10^6/L$. Zimnitsky's test: 1010-1010-1004-1010-1005---1012, total protein – negative. Bladder ultrasound: within normal limits.

Treatment given: the diagnostic cystoscopy and neoplasm excision under the general anaesthesia was performed on 09.06.16 (Fig. 5a-g).

Operative steps: after showing the external genitalia with antibacterial soap, 13 Fr ureterorenoscope was inserted and the bladder was filled with 300 ml of 0.02% Furacilini (during the operation). Then operative exploration of the bladder was performed. The golf-hole-shaped ureteral orifices were identified, the mucosal surface had common pink colour. The pathological changes around the ureteral orifices were not found out (Fig. 5a). Along the median line proximally to the vesical triangle, a two-mm-in-diameter pedunculated neoplasm was revealed with additional mucosal changes on the five-square-mm area (Fig. 5b). The excision of lesion was conducted (Fig. 5c). The bleeding from the operative site was minimal (Fig. 5d). Additionally the completed destruction of tumour bed and mucosal changes by means of coagulation was performed (Fig. 5e, f). The cysto-

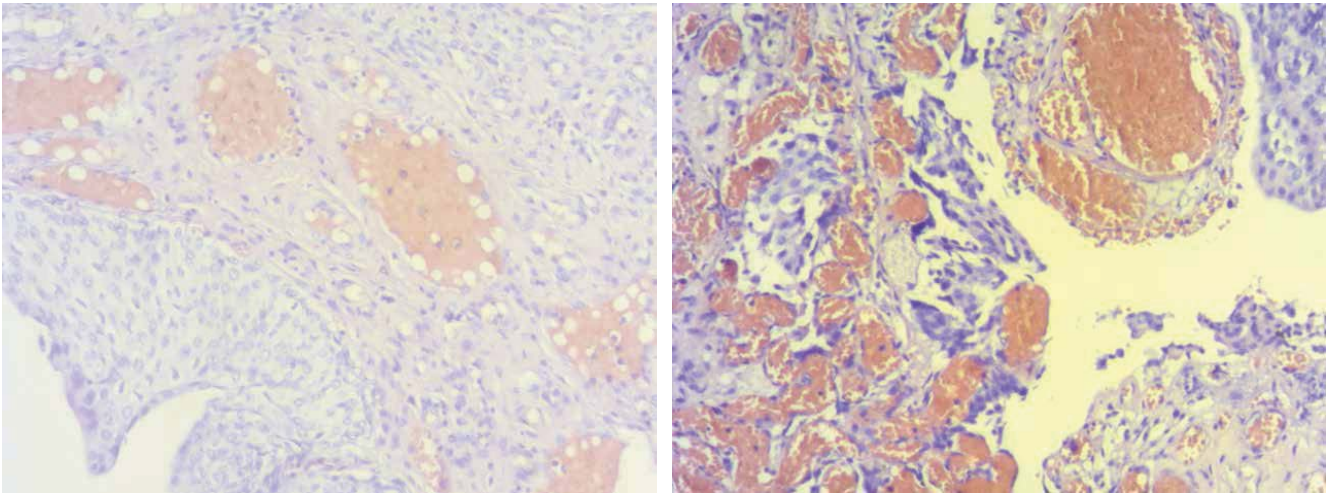


Fig. 4. Postoperative biopsic specimen (hematoxylin and eosin staining, $\times 200$) – transitional cell carcinoma

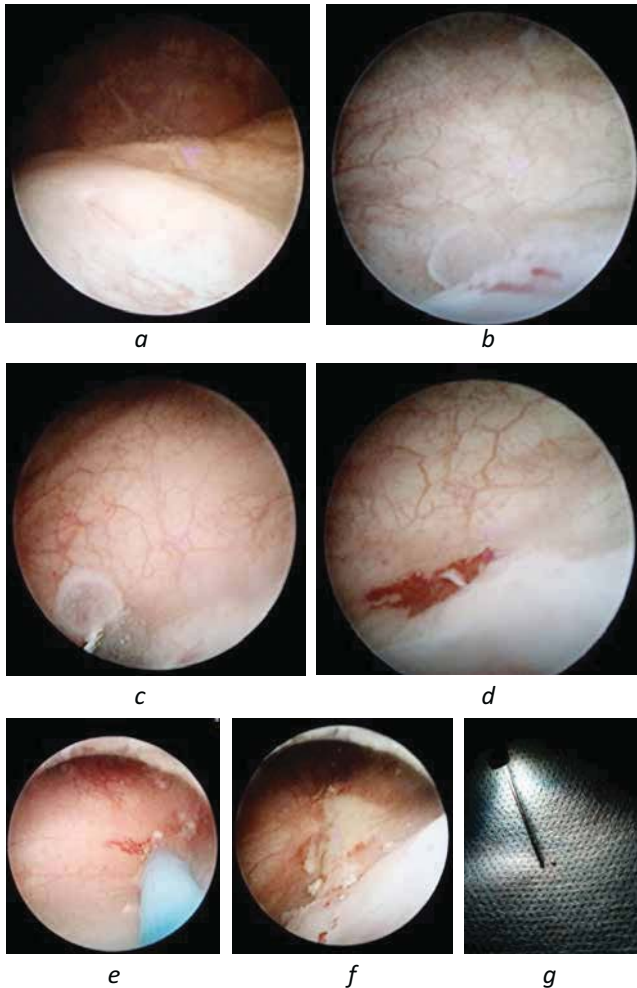


Fig. 5. Diagnostic cystoscopy and excision of neoplasm on 09.06.2016. The pathological changes around the ureteral orifices were not found out (a); pedunculated neoplasm was revealed with additional mucosal changes on the five-square-mm area (b); the excision of lesion (c); the bleeding from the operative site (d); the completed destruction of tumour bed and mucosal changes by means of coagulation (e, f); Postoperative gross specimen (g)

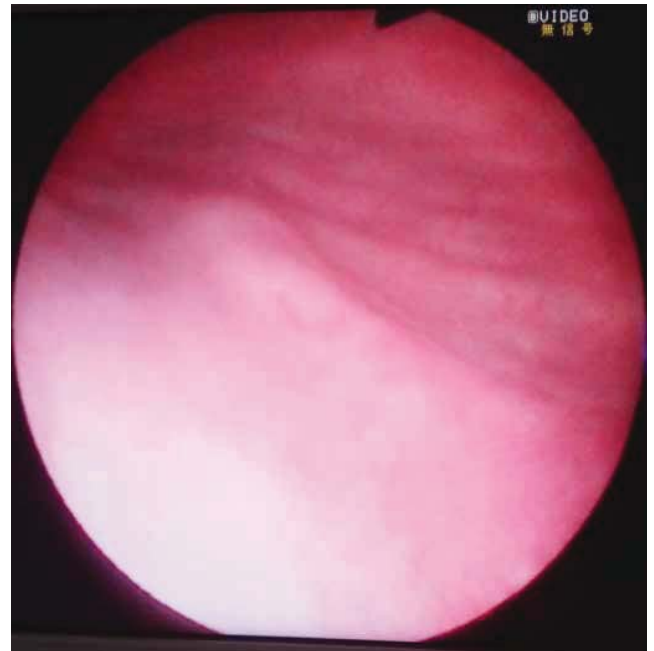

Fig. 6. Control cystoscopy on 08.11.2016 – within normal limits

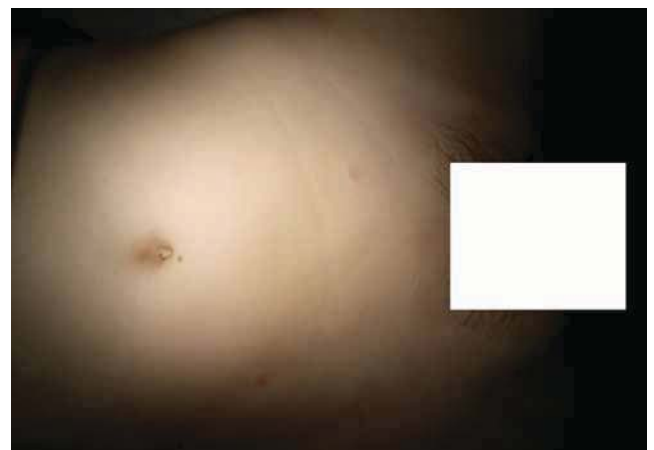

Fig. 7. The view of postoperative scars (in 8 months after transcutaneous cystoscopic operation)

Клінічний випадок

scope together with solution of Furacilini was removed. Postoperative gross specimen (Fig. 5g).

The postoperative period was uneventful. A symptomatic therapy was administrated. The patient was discharged recovered.

The patient was advised to continue follow-up by the paediatrician in the community, control urination and urinalysis weekly, take Proteflazid according to the clinical regimen during three months, continue uroseptics taking up to one month, and control bladder ultrasound in 6 months with the consultation of paediatric urologist in our clinic with the aim of establishing the surgical indications for control cystoscopy.

The readmission to our department was from 04.11.2016 to 11.11.2016. The patient had complaint of abdominal pain on the admission. *The discharge diagnosis:* bladder neoplasm (the transitional cell papilloma), postoperative period. Chronic superficial gastroduodenitis, exacerbation phase.

Additional clinical tests: CBC: HBG – 122 g/L, RBC – $4.03 \times 10^{12}/L$, WBC – $6.6 \times 10^9/L$, ESR – 4 mm/h; UA: urine specific gravity (SG) – 1.012, protein – negative, 1–2 squamous epithelial cells/HPF, 1–2 WBC/HPF. Nechiporenko test: WBC – $0.4 \times 10^6/L$, RBC – $0.8 \times 10^6/L$. Zimnitsky's test: 1010-1010-1004-1010-1005---1012, total protein – negative. Abdominal ultrasound: reactive changes of pancreas. Bladder ultrasound: normal (measures in filling state $86 \times 61 \times 87$ mm; measuring postvoid residual urine volume was not provided; additional lesions in the bladder were not detected). Fibrogastroscoy: superficial gastroduodenitis, pH 1.9. The child was examined by the paediatrician and gastroenterologist after further examination.

Treatment given: the diagnostic cystoscopy was performed on 08.11.2016. *Manipulation steps:* after showing the external genitalia with antibacterial soap, 13 Fr cystoscope was inserted and the bladder was filled with 300 ml of 0.02% Furacilini (during the manipulation). Then operative exploration of the bladder was performed. The golf-hole-shaped ureteral orifices were identified, the mucosal surface had common pink colour. There was no founded pathology around the orifices, vesical triangle and bladder bottom. The cystoscopy together with solution of Furacilini was removed (Fig. 6). A symptomatic therapy was administrated. The patient was discharged recovered.

The patient was advised to continue follow-up by the paediatrician and gastroenterologist in the community, control urination, urinalysis monthly, and bladder ultrasound in 12 months with the consultation of paediatric urologist in our clinic with the aim of establishing the surgical indications for control cystoscopy.

The view of the postoperative scars is shown in Fig. 7.

Benign neoplasm of bladder in paediatric patients is a very rare condition with the low grade of recurrence after surgery [16].

Of particular importance in childhood have recently become neoplasms, which are considered precancerous conditions (urothelial metaplasia, caruncle urethritis, etc.), which were previously very rare in childhood and have a proven link with the neuromuscular bladder dysfunction. We have written about such conditions before [7,14].

Thus, the minimally invasive techniques give the opportunity to perform even the radical operation with perfect cosmetic results and minimal damage that are crucial in childhood.

Ethics committee approval: Authors declared that the research was conducted according to the principles of the World Medical Association Declaration of Helsinki «Ethical Principles for Medical Research Involving Human Subjects», (amended in October 2013). The study was approved by the Ethical Committee of the Hospital and informed consent was signed by the patient representatives (parents) for the publication of related images and this report.

Written informed consent was obtained all parents who participated in this study.

Conflict of interest: The authors have no conflicts of interest to declare.

Financial disclosure: The authors declared that this study has received no financial support.

References/Література

1. Apoznański W, Rysiakiewicz J, Polok M, Rysiakiewicz K et al. (2015). Transurethral Resection of the Bladder Tumour as a Treatment Method in Children with Transitional Cell Carcinoma of the Bladder – Analysis of Our Material and Literature Review. *Adv Clin Exp Med.* 24 (3): 505–509. doi: 10.17219/acem/36600.
2. Berrettini A, Castagnetti M, Salerno A, Nappo SG, Manzoni G, Rigamonti W, Caione P. (2015). Bladder urothelial neoplasms in pediatric age: Experience at three tertiary centers. *Journal of Pediatric Urology.* 11 (1): 26. doi: 10.1016/j.jpuro.2014.08.008.
3. Campo G, Giannarini G, Pomara G, Manassero F, Pistolesi D, Selli C. (2012). Bladder papilloma in a 9-year-old girl: a case report. *Minerva Pediatr.* 64 (3): 361–3. PMID: 22555331.
4. Gabr AH, Elbadry M, Elsherief A, Tawfik ER. (2013). Computed tomography-virtual cystoscopy in the evaluation of a bladder mass: Could it replace standard conventional cystoscopy? *Arab J Urol.* 11 (4): 369–374. doi: 10.1016/j.aju.2013.06.007.
5. Fine SW, Humphrey PA, Dehner LP, Amin MB, Epstein JI. (2005). Urothelial neoplasms in patients 20 years or younger: a clinicopathological analysis using the world health organization 2004 bladder consensus classification. *J Urol.* 174 (5): 1976–80. PMID: 16217372. doi: 10.1097/01.ju.0000176801.16827.82.
6. Gao L, Tang DX, Li MJ, Xu S. (2014). Papillary Urothelial Neoplasm of Low Malignant Potential in a 9-year-old Boy: A Case Report. *HK J Paediatr (new series).* 19: 262–264.
7. Jurkiewicz B, Shevchuk D, Załęska K. (2017) Relationship between urothelial metaplasia and neuromuscular bladder dysfunction in children. *Paediatric Surgery (Ukraine).* 3 (56): 84–88

- [Jurkiewicz B., Шевчук Д. В., Załęska K. (2017). Зв'язок між метаплазією уротелію та нервово-м'язовою дисфункцією сечового міхура у дітей. Хірургія дитячого віку. 3 (56): 84–88]. doi 10.15574/PS.2017.56.84.
8. Litchinko A, Meyrat BJ, Nobile A, Raffoul L, Dushi G, Estremadoyro V. (2016). Hematuria in a 12-year-old child, a rare case of urothelial papilloma of the urinary bladder. *J Ped Surg Case Reports*. 7: 45–47. <http://dx.doi.org/10.1016/j.epsc.2016.02.011>.
 9. Patel R, Tery T, Ninan GK. (2008). Transitional cell carcinoma of the bladder in first decade of life. *Pediatr Surg Int*. 24 (11): 1265–8. doi: 10.1007/s00383-008-2251-4.
 10. Pati A, Sahoo RK, Mahapatra A. (2016). Urothelial Carcinoma in Pediatric Patient. *Indian J Surg*. 78: 229–231. doi:10.1007/s12262-015-1384-7.
 11. Polat H, Utangac MM, Gulpinar MT, Cift A, Erdogdu IH, Turcu G. (2016). Urothelial neoplasm of the bladder in childhood and adolescence: a rare disease. *Int Braz J Urol*. 42: 242–6. doi: 10.1590/S1677-5538.IBJU.2015.0200.
 12. Rifat UN, Hamadalla NY, Safi KCC, Al Habash SS, Mohammed M. Urothelial bladder tumour in childhood: A report of two cases and a review. *Arab J Urol*. 2015;13 (2):116–121. doi: 10.1016/j.aju.2014.11.002.
 13. Shevchuk D. (2018). Mini-invasive surgery on the lower urinary tract for neuromuscular bladder dysfunction in children. *Paediatric Surgery (Ukraine)*. 3 (60): 80–84 [Шевчук Д.В. (2018). Мініінвазивні оперативні втручання на нижніх сечових шляхах у лікуванні нервово-м'язової дисфункції сечового міхура у дітей. Хірургія дитячого віку. 3 (60): 80–84]. doi 10.15574/PS.2018.60.80.
 14. Shevchuk D. V. (2016). A Rare Case of Urethral Caruncle Complicated with Neuromuscular Bladder Dysfunction in a 9-Year-Old Girl. *Paediatric Surgery (Ukraine)*. 1–2 (50–51): 97–100. <http://www.mif-ua.com/archive/article/43586>.
 15. Shevchuk DV, Rusak PS, Vyshpinskyi IM, Zarembo VR. (2015). Zastosuvannia cherezshkirnoi tsystoskopii pry vydalenni storonnoho tila u dytyny, khvoroi na nervovo-m'язovu dysfunktsiiu sechovoho mikhura. *Naukovyi visnyk Uzhhorodskoho universytetu (seriia Medytsyna)*. 2 (52): 124–129 [Шевчук ДВ, Русак ПС, Вишпінський ІМ, Заремба ВР. (2015). Застосування черезшкірної цистоскопії при видаленні стороннього тіла у дитини, хворой на нервово-м'язову дисфункцію сечового міхура. Науковий вісник Ужгородського університету (серія Медицина). 2 (52): 124–129]. http://nbuv.gov.ua/UJRN/UN-UMED_2015_2_29.
 16. Thomas G, Gera P, Arbuckle S, Cohen R. (2006). Transitional cell papilloma of the bladder in a child: A case report and review of literature. *Journal of Pediatric urology*. 2 (1): 59–62. <http://dx.doi.org/10.1016/j.jpurol.2005.05.009>.

Відомості про авторів:

Шевчук Дмитро Володимирович – к.мед.н., доц., лікар-уролог дитячий та лікар-хірург дитячий хірургічного відділення №2 КНП «Житомирська обласна дитяча клінічна лікарня», доц. каф. медико-біологічних дисциплін Житомирського державного університету імені Івана Франка, доц. каф. урології НУОЗ України імені П. Л. Шупика. *Researcher ID* C-3853–2016; <https://orcid.org/0000-0002-3466-3430>.

Заремба Віталій Ростиславович – лікар-хірург дитячий вищої кваліфікаційної категорії КНП «Житомирська обласна дитяча клінічна лікарня» Житомирської ОР. Адреса: Житомирський район, с. Станишівка, шосе Сквирське, 6. <https://orcid.org/0000-0003-4231-4342>.

Васянович Андрій Васильович – зав. дитячого відділення Житомирського обласного патологоанатомічного бюро. Адреса: Житомирська обл., м. Житомир, вул. Р. Шухевича, 2А.

Стаття надійшла до редакції 29.01.2022 р., прийнята до друку 20.04.2022 р.